

# Brain, Memory, and Amnesia

Ryan Zhang<sup>1</sup> and Thomas Andl<sup>2#</sup>

<sup>1</sup>Sycamore High School

<sup>2</sup>University of Central Florida

#Advisor

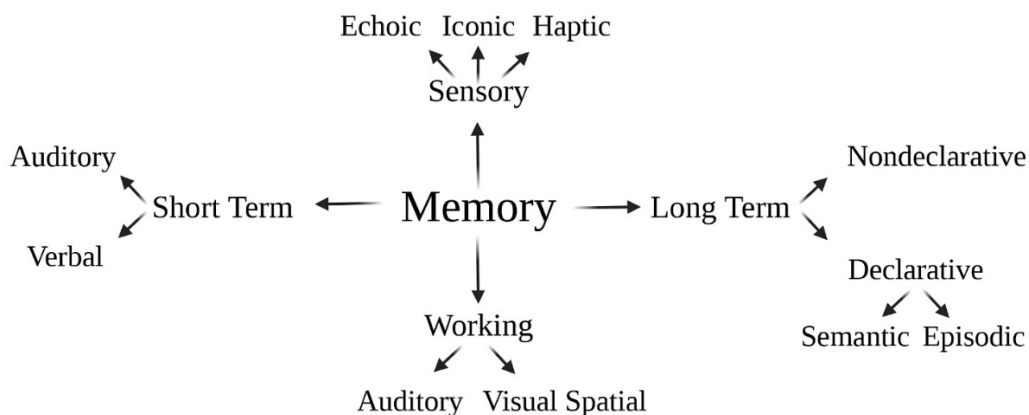
## ABSTRACT

Amnesia is a large-scale and long-term memory loss. Complications of amnesia, including the inability to create new memories and learn new things, severely reduce the quality of an individual's life. In the last three centuries, many famous clinical studies, including the one involving Henry Molaison (H.M), have been completed, furthering our understanding of the brain's memory system and amnesia. Especially, a variety of psychological and neurological causes of amnesia have been identified. Different treatments are available for different types of amnesia; however, due to the extensive causes of amnesia, finding a common cure has proven to be difficult. This review will focus on our current understanding of the memory system and history of amnesia as well as the types, causes, preventive measures, and potential treatment strategies of amnesia.

## Introduction

Memory is a process by which the brain recalls the information that it has learned and stored. Everyone can forget things but that does not necessarily mean people have amnesia. Memory loss is also considered to be a normal part of the aging process. Approximately forty percent of the population suffers from different types and degrees of memory loss (Wikidoc, 2021). Therefore, it is not uncommon to see many misconceptions regarding amnesia and its symptoms. In fact, Amnesia is defined as a profound loss of memory in an individual often caused by drugs or alcohol, brain injury, or certain types of illness (Allen, 2018). Patients who suffer from amnesia may struggle to recall past events and previously known information. They may also find it difficult to create new memories and learn new skills.

## Overview of the Memory System

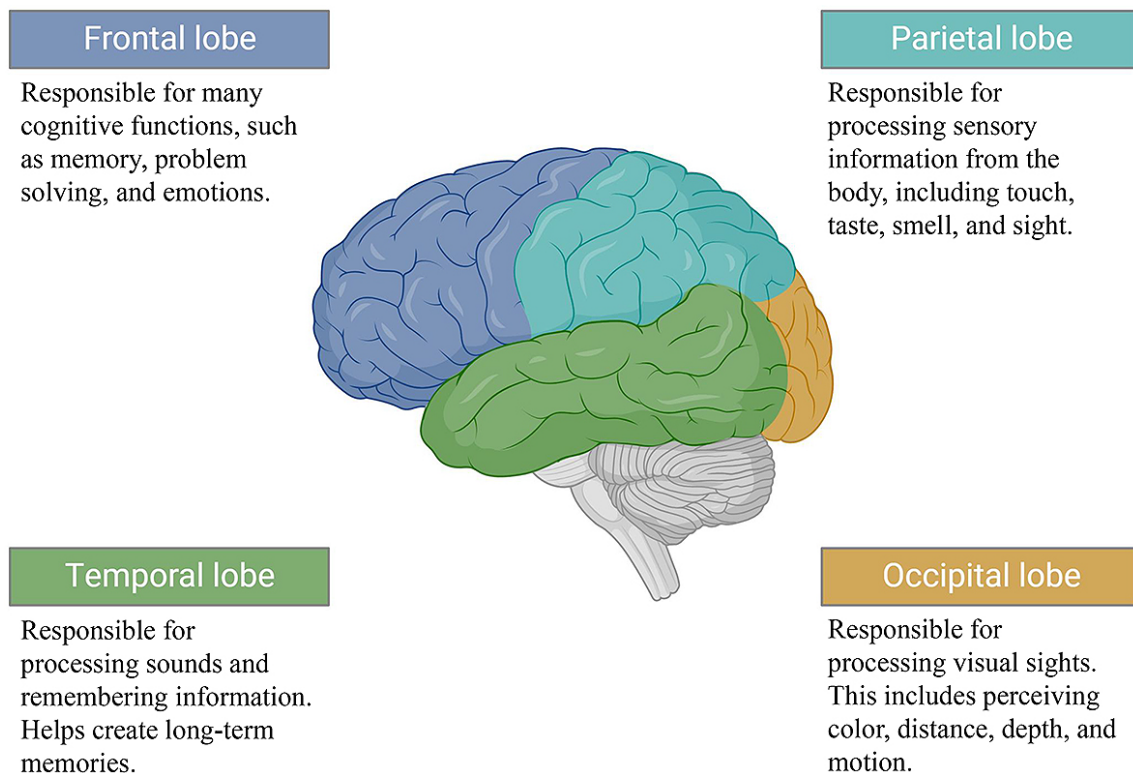


**Figure 1. Overview of the Memory System.** Memory can be divided into four main categories: sensory, short term, working, and long term. Each category can be further split into memory-specific branches.

In the memory system, there are sensory memory, short-term memory, working memory, and long-term memory (figure 1). Sensory memories are from the five human senses, including hearing, vision, touch, smell, and taste, and stored for only a few seconds. Short-term memory is super quick and only stores information briefly. It can last from a few seconds to a few days and can be forgotten thereafter. Working memory processes and stores the information for a short time, which is just long enough for our brain to use it (Heerema, 2022). Long-term memory has two major types: declarative and nondeclarative (figure 1). Declarative memory allows people to consciously recollect events and facts. Human beings can explicitly and constantly recall or recognize events and facts. For example, remembering exactly what happened at the wedding six years ago is a declarative memory. Declarative memory includes episodic memory, which refers to the ability to recall past events that happened to you, and semantic memory, which is the memory of general, context-free facts and information. Nondeclarative memory, also known as procedural memory, on the other hand, is not recalled and reflected with consciousness but rather with instinct. It consists of a “heterogeneous” collection of abilities, such as skills and habits, which do not require conscious recollection. When riding a bike, there is no need to constantly think about how to ride the bike as well as previous performance; it is instinctive and performed automatically without conscious thinking. Likewise, brushing teeth is an ingrained skill that does not require frequent thoughts.

### Where Is Memory Stored?

Contrary to popular belief, memory isn’t stored in only one location within the brain. Depending on the type of memory, different regions of the brain are involved (Queensland Brain Institute, 2018).



**Figure 2. Overview of the Brain’s Lobes.** The brain has four main lobes, including the frontal lobe (in blue), the temporal lobe (in green), the parietal lobe (in teal), and the occipital lobe (in yellow). The cerebellum is underneath the occipital lobe and the parietal lobe. The graph was created with BioRender.com

## *Explicit Memory*

Explicit memory is a type of long-term memory for the recollection of facts and events. Explicit memory is also known as declarative memory and can be divided into episodic and semantic memory. While episodic memory is the ability to remember specific events or things that have happened, semantic memory is the ability to remember general facts and information, such as who the president is (Cherry 2022). Explicit memories are stored in the hippocampus, neocortex, and amygdala (Queensland Brain Institute, 2018).

### Hippocampus

The hippocampus is a complex brain structure located deep in the temporal lobe of the brain and plays an important role in learning and forming new memories (Anand et al., 2012). The hippocampus is where episodic memories are formed. It is also involved in memory consolidation and spatial awareness. However, recent studies show that the hippocampus is not necessary for permanent or motor memory (Queensland Brain Institute, 2018).

### Neocortex

The neocortex is the largest part of the cerebral cortex and is a part of all four main lobes. It is a wrinkly sheet of neural tissue that forms the outside surface of the brain and makes up approximately half the volume of the human brain (Bennet, 2019). The neocortex is used for sensory perception, motor commands, spatial reasoning, and language. Temporary memories stored in the hippocampus move into the neocortex and become general knowledge, also known as semantic memory (Queensland Brain Institute, 2018).

### Amygdala

The amygdala is an almond-shaped structure in the temporal lobe and is involved in attaching emotions to memories (Queensland Brain Institute, 2018). The joyous emotions of adopting a dog or the sadness when a family member dies are all the result of the amygdala's work. Furthermore, the amygdala has a role in forming memories related to fear (Baxter & Croxson, 2012). For example, if the smell of rubbing alcohol precedes the pain of a needle, the amygdala will connect rubbing alcohol with the fear of imminent pain after a few times of exposure. Because it is a key component in fear conditioning, the amygdala is also connected to post-traumatic stress disorder (PTSD) and other stress-related mental disorders. These strong emotions are hard to forget, making the amygdala an integral part of the memory system.

## *Implicit Memory*

Implicit memory, also known as nondeclarative memory, is an unconscious and automatic memory that does not require thinking to remember the information of the past (Gropper, 2020). Tying shoes, brushing teeth, and knowing how to play the piano are examples of implicit memory. Implicit memory is stored in the basal ganglia and cerebellum (Queensland Brain Institute, 2018).

### Basal Ganglia

The basal ganglia are a set of structures deep inside the brain. They are located in the temporal lobe and primarily controls motor movement, emotional behaviors, and habit learning (Lanciego et al., 2012). For example, when learning how to play an instrument like the piano, the basal ganglia is used to process key pressing into nondeclarative memory. If a patient were to lose their declarative memory, they would instinctively still be able to play the piano keys as it is stored as nondeclarative memory.

### Cerebellum

The cerebellum is a structure located in the back of the brain between the cerebrum and the brain stem. It is under both the temporal lobe and occipital lobe. The cerebellum controls the fine movements of our body including walking, standing, balance, and coordination (Guy-Evens, 2021). For example, walking, picking up small items, dialing the phone, tying shoelaces, using chopsticks, and playing piano keys louder or softer are all movements that the cerebellum controls.

### *Working Memory*

Working memory is related to short-term memory and is involved in remembering small details, which can be used for a future task. For instance, memorizing somebody's phone number to call them later is an example of working memory, however, one could still forget the phone number later. Working memory is different from long-term memory, which holds all the information gathered over an individual's lifetime (Cowan, 2014).

### Prefrontal Cortex

The prefrontal cortex is the cerebral cortex covering the front part of the frontal lobe. It is involved in many cognitive functions and is thought to have an important role in working memory function by encoding and updating memories (D'Ardenne et al., 2012). There are two sides to the prefrontal cortex. The left side focuses on verbal working memory, such as memorizing the address of a location, and the right side focuses on spatial memory, such as the general surroundings of the location (Queensland Brain Institute, 2018).

## **The History of Amnesia**

Although memory loss has been described since ancient times, it was not recognized as a clinical disorder until the eighteenth century. In 1763, François Boissier de Sauvages designated amnesia as a medical disorder for the first time in his systematic classification of illnesses among mental illnesses. Many different causes of amnesia were specified, and different types of amnesia were determined based on the etiologies at that time, such as emotional suffering, trauma, intoxication, or stroke et al (Langer, 2021).

In the early nineteenth century, more features of amnesia were recognized. These features include the degree of memory loss, nature of onset, symptom durability, and constancy (Langer, 2021). By reviewing these characteristics, a doctor is able to determine whether amnesia can be defined as complete or partial, sudden or progressive, temporary or stable, and intermittent or continuous. A poor prognosis was noted in patients with longer chronicity and greater intensity of amnesia. Temporal aspects of amnesia were emphasized in the late nineteenth century. As a result, anterograde and retrograde amnesia have been described as different types of amnesia. Théodule Ribot's law of regression was hypothesized in 1881 and states that recently formed memories would be impaired to a greater extent than old memories with retrograde amnesia (Langer, 2021).

Entering the twentieth century, the main focus of clinical research was to define the normal process of memory. Analyzing different cases of amnesia served as an important research tool, and many studies have made a significant contribution to the current understanding of the memory process and amnesia neuroanatomy.

### **The H. M. Case and its Contributions to Defining the Memory Process**

Among all the amnesia case studies, the Henry Molaison (H.M.) case is the most famous case. H. M is the best-known individual patient in the history of neuroscience, and his case has taught us a great deal about the cognitive and neural organization of memory (Corkin, 2002, 153-160 & Squire, 2009). It is a case that presents a "pure" form of amnesia and helped establish fundamental principles of memory (Squire, 2009).

After a childhood bicycle accident, H. M suffered from intractable minor and major seizures before becoming debilitated at age 27. An experimental surgical resection of the bilateral medial temporal lobes (MTL) and hippocampus was performed in 1953 by neurosurgeon Dr. William Scoville in an attempt to reduce H. M's seizures (Corkin et al., 1997). Surprisingly, although the seizure was controlled, significant memory impairment, especially his ability to create new memories, was noted after surgery. For example, he could be introduced to new people and instantly forget who they were. At the time, this was unprecedented, so H. M's memory hindrance after MTL resection attracted the attention of many physicians and scientists. The case led to more extensive neuropsychological assessments to be performed, and eventually, many groundbreaking features of the brain and H. M's memory loss were revealed (Squire, 2009).

Before the H. M. case, amnesia was generally thought to be the inability to learn anything new. However, H. M still interestingly retained the ability to acquire new visuomotor skills. For instance, when HM was shown a five-pointed star with a double contour, he was asked to trace its outline with a pencil. He was only allowed to see his hand and the star shown in a mirror. After ten experiments drawing different objects, H. M acquired the mirror-drawing and visuomotor skills required to complete the task and showed excellent retention across three days. However, at the end of testing, he had no recollection of having done this task before (Squire, 2009). This was the first evidence showing the brain may be compartmentalized and have different regions to store different kinds of memory.

H. M also had a limited capacity for sustained attention. He was able to have conversations and repeat simple strings of digits. Using rehearsal techniques, he was able to recall the information for a limited amount of time. However, when a new topic was brought up or H. M's attention was shifted, he would completely forget about the previous conversations (Squire, 2009). Notably, H. M's other cognitive abilities were not affected by the surgery. His personality, intelligence, and language ability were the same as he had before the surgery (Covington & Duff, 2018).

These unique features of H. M's memory loss after MTL helped scientists define the memory process. H. M was unable to create new memory after MTL damage, suggesting that MTL is a crucial component needed for episodic memory. This has been confirmed by later studies and is now a well-accepted theme. (Langer, 2021 & Corkin, 2002, 153-160 & Rosenbaum et al., 2011, 47-63). However, H. M's ability to learn new motor skills and his immediate memory span even after MTL damage supported the theory that the brain structures relating to working memory and nondeclarative memory are not connected to the MTL (Langer, 2021 & Corkin, 2002, 153-160 & Rosenbaum et al., 2011, 47-63). With further research, it is now known that the brain structures involved with working and nondeclarative memory processes include the basal ganglia, cerebellum, amygdala, neocortex, and prefrontal cortex. The dissociation of different memory forms in the H.M. case taught us an important concept that memory is not a unitary, indivisible system. In fact, memory consists of several separate systems that have different targets, contents, durations, and neural bases (Covington & Duff, 2018). This was truly the first time that researchers have learned about the detailed compartmentalization within the brain responsible for different types of memory, and it may not have been possible without Henry Molaison.

## Causes of Amnesia

There are various causes of amnesia, which can be generally classified into two main groups: psychological causes and neurological causes. Psychological causes refer to a patient's state of mind and mental wellbeing, whereas neurological causes are associated with physical damage to the patient's brain.

### Psychological Causes

Psychological causes include abuse, post-traumatic stress disorder (PTSD), war, extreme stress, and natural disasters. These traumatic events may lead to overwhelming stress, which triggers periods of temporary amnesia (Cleveland Clinic, 2020). Other incidents, such as extreme physical exertion, for example, can lead to episodes of transient global

amnesia. In these cases, there is no physical damage to the brain, so full memory is usually restored (Harrison et al., 2017).

## Neurological Causes

Neurological, or organic amnesia, is a cause of amnesia that is a consequence of physical damage to the brain. The damage can be caused by multiple reasons, including trauma to the head, surgery, infection, seizures, or disease (i.e., Alzheimer's). As a result, a patient may develop a variety of anterograde, retrograde, and posttraumatic amnesia. In these cases, because of physical damage to the patient's brain, there is no common treatment, and the amnesia could remain permanent (Mayo Clinic, 2020).

## Types of Amnesia

Amnesia can be temporary or long-lasting. As different illnesses can lead to amnesia, there are many types of amnesia. A patient can have more than one type of amnesia. In addition, different types of amnesia may share similar features.

### Retrograde Amnesia

Retrograde amnesia (RA) is a type of amnesia that refers to the loss of information acquired before the amnesia occurs (Kumar, 2021). This condition is often diagnosed after the medial temporal lobe is damaged, affecting both episodic and semantic memory. Therefore, patients who suffer from retrograde amnesia have difficulty remembering the events that occurred before the amnesia-triggering event (Reed et al., 1998). However, the length and severity of the lapse in memory differ in each patient. For example, one patient may lose memory only in the past three years, while other patients may lose memory in the last ten years. For H. M, his retrograde amnesia was determined to be approximately 11 years, meaning that H. M. could still remember events that occurred 12 years ago while he completely forgot the last 11 years of his life (Heaning, 2022). Generally speaking, older memories can be retained, and most patients can recall their childhood.

### Anterograde Amnesia

Anterograde amnesia (AA) is a type of amnesia that refers to an individual's inability to create new memories (Cleveland Clinic, 2020). In some cases, patients lose the ability to learn new information indefinitely. Depending on the causes, anterograde amnesia can be both temporary and permanent. If the onset is caused by a psychological root, then the amnesia is likely temporary, and memory will return to normal thereafter. However, if amnesia is caused by damage to the brain, then it will be permanent. As seen in the case of H. M, he suffered permanent damage to the medial temporal lobe and hippocampus as a result of his surgery. Thus, his anterograde amnesia was permanent. The introduction of anterograde amnesia on its own is quite rare. It is usually diagnosed with some level of retrograde amnesia, and studies have found that the severity of anterograde amnesia is often directly correlated with the severity of retrograde amnesia (Smith et al., 2013).

### Dissociative Amnesia

Dissociative amnesia, a type of psychological amnesia, is a disorder that affects approximately 1.0-2.6% of the population (Wikidoc, 2021). Dissociative amnesia is distinguished by the memory gaps it causes (Leong et al., 2006). It has three major patterns: localized, generalized, and fugue. Localized dissociative amnesia is the result of a specific traumatic event that an individual may experience. For example, if the patient experiences a very severe car accident

without injury, they may later find themselves having no recollection of that specific event but can easily recall other details of the day. In contrast, generalized dissociative amnesia affects a much broader portion of a patient's life, which is caused by traumatic events or immense stress, and the patient may forget who they are, where they live, or their family and friends. For instance, a soldier returning home after experiencing the horrors of war may struggle to remember who they are. Finally, fugue dissociative amnesia is a form of generalized dissociative amnesia where patients may suddenly find themselves in a new location with no explanation (Cleveland Clinic, 2020).

For dissociative amnesia, there is no physical damage to the brain; thus, it is treatable. In many cases, the conditions can completely resolve on their own. However, patients can also seek therapy to help with memory recovery.

## Post-traumatic Amnesia

Posttraumatic amnesia (PTA) is a type of amnesia that occurs immediately after a traumatic brain injury. This happens to a lot of athletes in sports. When taking a heavy hit to the head, the athletes may be unconscious or even in a coma. After regaining consciousness, the person may appear to be disoriented, confused, agitated, distressed, or have problems remembering who they are. In these cases, it is important to note that this stage will eventually pass (Headway, n.d.). The amount of time during which the patient is unconscious in effect plays a huge role in how the patient will recover. The shorter the duration is, the higher the chance that the patient can make a recovery to the pre-injury state. However, as time passes, the chance of a good recovery substantially diminishes (Headway, n.d.). In this case, depending on the severity of the damage, the patient can expect to develop some forms of anterograde or retrograde amnesia and may also suffer from dissociative amnesia due to the traumatic event.

## Childhood Amnesia

Childhood amnesia, also known as infantile amnesia, is the inability to remember early episodic memories. This is an extremely common form of amnesia and is believed to occur due to the underdevelopment of the infant brain (Vitelli, 2014). There are rare cases of adults being able to store and recall numerous events from their early childhood. When the brain and its memory system begin the process of learning and storing memory in these early years, they may not develop as completely and as quickly as needed. As such, the underdevelopment causes the early memories of childhood to become increasingly inaccessible and difficult to recall as the child grows. Almost every adult studied to date has infantile amnesia, and most people have trouble recognizing the events that occurred before the age of four (Anderson 2022). Other causes, such as neglect, cognitive disability, poverty, and trauma, have also been identified as contributing factors to the severity of childhood amnesia (Alberini et al., 2017).

## Transient Global Amnesia

Transient global amnesia is a temporary form of amnesia that results in sudden and complete anterograde memory loss. Cases of transient global amnesia occur most commonly in individuals between the ages of 50 and 80 with approximately 23.5-32 cases per 100,000 people, which is approximately four times more than the number of cases in the general population (5.2-10 per 100,000 people) (Wikidoc, 2021). Transient global amnesia is often attributed to periods of extremely demanding physical activity and high stress. However, it has been noted that transient global amnesia occurs more commonly in people who have a history of ischemic heart disease, migraines, and hyperlipidemia (Nehring et al., n.d.). People who suffer from transient global amnesia are aware of who they are but may have confusion as to who other people are. Transient global amnesia is a temporary condition that resolves within 24 hours, with most cases lasting between one and ten hours. Once resolved, transient global amnesia rarely occurs again and will not lead to neurological deficiencies or damage. As such, it is no more than a common neurological condition (Mayo Clinic, 2022).

## Korsakoff Syndrome

Korsakoff Syndrome is a memory disorder that occurs due to a severe thiamine (vitamin B-1) deficiency in the brain. There may be other factors that contribute to Korsakoff's Syndrome, but it is mainly and most commonly caused by alcohol abuse (Alzheimer's Association, n.d.). Thiamine helps the brain produce energy by generating sugar. When the thiamine level is too low, there will not be enough energy to keep the brain functioning properly. Research has shown that reduced thiamine levels disrupt signal transmission among brain cells, leading to microscopic bleeding and scar tissue damage. As a result, the brain sometimes develops a neurological condition called Wernicke encephalopathy (Alzheimer's Association, n.d.). Wernicke encephalopathy causes permanent brain damage and will leave the patient delirious, confused, and uncoordinated. Following the development of Wernicke encephalopathy, the patient will likely develop Korsakoff's syndrome and suffer from profound memory loss, including major problems in learning new information as well as difficulty in recalling the past (Heller, 2015). Some patients do not experience Wernicke encephalopathy but can still develop Korsakoff syndrome. Both Wernicke encephalopathy and Korsakoff syndrome are medical emergencies and must be treated immediately. Thiamine injections may alleviate some symptoms within a week. However, it could take months to see an improvement in the recovery. While approximately 25% of patients who develop Korsakoff syndrome can completely recover, about 50% of patients only recover but not to a pre-amnesic state (Alzheimer's Association, n.d.). The recovery is likely correlated with the level of damage to the brain.

## Amnesia Diagnosis

A series of comprehensive exams need to be performed to establish the diagnosis and determine the possible causes of memory loss, such as brain tumors, Alzheimer's disease, dementia, or depression, etc.

## Medical History

The evaluation will start with the patient's medical history. Generally, a family member will also take part and assist the individual with memory loss. The doctor will ask questions regarding many topics, including when the problem started, family history, alcohol use, whether the memory loss is recent or long-term, and any other possible symptoms (Mayo Clinic, 2020). Using this information, the doctor will be able to rule out other possible causes for memory loss, such as Alzheimer's disease or dementia. Questions regarding the frequency of memory lapses, types of things forgotten, and triggering factors can further assist in determining the type of amnesia (Mandal, 2019). For example, if a patient states that they are a heavy drinker, then the doctor can probably assume that amnesia could be a form of Korsakoff syndrome.

## Neurological Examination

The goal of this test is to determine any physical problems, which could suggest a form of amnesia. For example, in Korsakoff syndrome, a common side effect is numbness in the fingers and toes. If a patient reports this loss of sensation, then the doctor will certainly understand that amnesia could be caused by Korsakoff syndrome. As such, in this test, the doctor will assess the patient's speech, vision, senses, spatial skills, and reflexes (Mayo Clinic, 2020). Other sensory functions and physiological aspects of the brain and nervous system may also be tested. Patients will also be asked to name objects, draw pictures, follow commands, and write sentences. They may need to walk a short distance, as an abnormal walking pattern may be an indication of medical conditions in the brain (NYU Langone Health, n.d.).



## Cognitive Examination

The patient can take a full cognitive examination. This may be done through the administration of the Mini-Mental State Examination (MMSE). The MMSE is an 11-question test that measures five areas of cognitive function: orientation, registration, attention and calculation, recall, and language (Kurlowicz, 1999). With a maximum score of 30, any score under 24 indicates cognitive deficiency (Kurlowicz, 1999). In addition, the doctor can ask some simple questions, such as where they are and where the patient lives, to evaluate the cognitive function (Mayo Clinic, 2020). These general questions can help the doctor determine the severity of recent and long-term memory loss and decide what type of help the patient may need.

## Magnetic resonance imaging (MRI)

A magnetic resonance imaging scan, or MRI, is a test that will scan the brain for potential damage. The patient will be placed inside a tube-shaped magnet. The machine will use its powerful magnetic field, along with radio pulses, to create not only cross-section images of the patient's brain but also a full three-dimensional model (Johns Hopkins Medicine, 2021). These diagrams help the doctor identify areas of brain damage and rule out other possibilities, such as brain tumors and infections (NYU Langone Health, n.d.).

## Electroencephalogram (EEG)

Doctor may also conduct an electroencephalogram (EEG) on the patient. Because the brain communicates with electrical signals, this test will measure the brain's electrical activity via a series of electrodes attached to the patient's head. Any changes in brain activity detected by EEG can help diagnose epilepsy (a cause of amnesia), tumors, and brain damage (Mayo Clinic, 2022).

## Positron Emission Tomography (PET) scan

Positron emission tomography, or PET scan, is another type of diagnostic test that a doctor may perform. This test is performed by injecting a radioactive drug, called a radiotracer, into the veins of a patient (Cleveland Clinic, 2020). The radiotracer uptake in the brain region receives a PET scan (IAEA, 2016). The scan will show a detailed image of the brain's physiology. Doctors will use the information collected to gauge whether there is damage in the brain.

## Amnesia Prevention

Practicing healthy habits and living a healthy life can effectively help prevent or reduce the risk of developing amnesia. Obtaining annual eye checkups and taking medications to reduce dizziness will help prevent falls and injuries. Wearing protective headgear while biking can reduce the risk of head trauma. Eating a healthy diet full of fruits, vegetables, whole grains, and low-fat proteins can help prevent strokes and other cardiovascular problems that may invoke amnesia (Ratini, 2019). Dehydration has been proven to negatively affect cognitive skills, so staying hydrated is crucial. Studies have also shown that consistent aerobic exercise can increase the size of the hippocampus, improving memory and thinking skills (Godman, 2014). Finally, getting eight hours of sleep every night and staying mentally active, such as playing an instrument, reading books, or doing puzzles, can improve mental health.

## Amnesia Treatment

Amnesia can be resulted from diverse causes; therefore, it is difficult to create a standard treatment regime. In many psychological cases, amnesia heals on its own. However, in permanent cases, there is a variety of cognitive therapies and medications that can be used to alleviate the symptoms of amnesia.

### Eye Movement Desensitization and Reprocessing

As many forms of amnesia are caused by traumatic events or PTSD, reducing the level of stress can be extremely beneficial in treating amnesia. Eye movement desensitization and reprocessing (EMDR) is a form of treatment that can diminish the severity of emotion and feedback associated with traumatic events (American Psychological Association, 2017). EMDR attempts to change the way by which the traumatic event is stored in the brain by having the patient to complete a series of eye movements (Pinto et al., 2021). The treatment helps reduce stressful and emotional memories of the past, thus reducing the chance of stress-induced amnesia.

### Neurofeedback

Neurofeedback is a method of improving the patient's ability to remember information. It is a sort of biofeedback that works by retraining many brain functions (Pinto et al., 2021). Usually, an electrode will be placed on the patient's brain to measure brain waves. For every activity that the brain completes, positive or negative feedback will be produced based on its desirability. In this way, the brain is essentially being re-coded to respond to a stimulus in a certain way (Marzbani et al., 2016). In most cases, neurofeedback is effective in refining a patient's ability to remember information and improving quality of life.

### Cognitive Therapy

In some cases, therapy can also be effective for helping people who suffer from amnesia. Cognitive therapy is a psychological treatment that will help patients solve challenges in their life and find ways to work around their problems (Davis, 2022). Cognitive therapy will also help patients change the way in which they think about certain situations. Instead of thinking pessimistically, the patients will learn to be aware of their unhelpful thoughts and develop the skills and brain concentration to recover memory (Pinto et al., 2021 & Davis, 2022).

### Vitamins

While there is currently no medication to treat amnesia, there are a variety of vitamins that can be taken to help improve memory and cognitive function. Vitamin B6 is very important for brain development. Taking vitamin B6 will help build neurotransmitters, which are important chemical messengers in the brain and can potentially improve brain functionality and memory (Pinto et al., 2021). Vitamin B9, also known as folic acid, is essential for brain function and helps maintain a healthy mental and emotional status. Taking vitamin B9 will reduce homocysteine levels. High homocysteine levels negatively affect brain cell functionality (Pinto et al., 2021). As a result, vitamin B9 can reduce anxiety and depression while also enhancing cognitive activity. Vitamin B12 can also benefit the brain and memory. Studies have shown that vitamin B12 is connected to memory loss (Berkheiser, 2018). Thus, taking vitamin B12 can boost memory. Finally, vitamin B1 is also an option. Taking vitamin B1 will boost thiamine levels. As discussed with Korsakoff's syndrome, low thiamine levels can cause Wernicke's encephalopathy, leading to permanent brain damage. Therefore, receiving a thiamine boost using vitamin B1 can be very beneficial.

## Conclusion

Amnesia has been around for ages and affects millions of people worldwide. The understanding of the memory system and amnesia have been significantly deepened since François Boissier de Sauvages first designated amnesia as a disorder in the eighteenth century. Although many questions in these fields still remain unanswered, with ever evolving technology and further research, there is no doubt that we are getting closer and closer to decoding the complicated memory system and pathophysiology of amnesia and developing better therapeutic strategies.

## Reference

- Alberini, C. M., & Travaglia, A. (2017). Infantile amnesia: A critical period of learning to learn and remember. *The Journal of Neuroscience*, 37(24), 5783–5795. <https://doi.org/10.1523/jneurosci.0324-17.2017>
- Allen, R. J. (2018). Classic and recent advances in Understanding amnesia. *F1000Research*, 7, 331. <https://doi.org/10.12688/f1000research.13737.1>
- Alzheimer's Association. (n.d.). *Korsakoff syndrome*. Alzheimer's Disease and Dementia. <https://www.alz.org/alzheimers-dementia/what-is-dementia/types-of-dementia/korsakoff-syndrome>
- American Psychological Association. (2017, July 31). *Eye movement desensitization and reprocessing (EMDR) therapy*. American Psychological Association. <https://www.apa.org/ptsd-guideline/treatments/eye-movement-reprocessing>
- Anand, K. S., & Dhikav, V. (2012). Hippocampus in health and disease: An overview. *Annals of Indian Academy of Neurology*, 15(4), 239. <https://doi.org/10.4103/0972-2327.104323>
- Anderson, A. (2022, April 28). *What is infantile amnesia?* WebMD. <https://www.webmd.com/children/what-is-infantile-amnesia>
- Baxter, M. G., & Crosson, P. L. (2012). Facing the role of the amygdala in emotional information processing. *Proceedings of the National Academy of Sciences*, 109(52), 21180–21181. <https://doi.org/10.1073/pnas.1219167110>
- Bennett, C. (2019, March 6). *What is the neocortex?* News - Medical Life Sciences. <https://www.news-medical.net/health/What-is-the-Neocortex.aspx>
- Berkheiser, K. (2018, June 14). *9 health benefits of Vitamin B12, based on science*. Healthline. <https://www.healthline.com/nutrition/vitamin-b12-benefits>
- Cherry, K. (2022, May 20). *What is Episodic Memory*. Verywell Mind. <https://www.verywellmind.com/what-is-episodic-memory-2795173#:~:text=Episodic%20vs.-,Semantic%20Memory&text=Semantic%20memory%20is%20focused%20on,as%20explicit%20or%20declarative%20memory>
- Cleveland Clinic. (2020). *Dissociative amnesia: Symptoms, causes, Management & Treatment*. Cleveland Clinic. <https://my.clevelandclinic.org/health/diseases/9789-dissociative-amnesia>

- Cleveland Clinic. (2020, August 10). *PET scan: Tests, types, procedure*. Cleveland Clinic. <https://my.clevelandclinic.org/health/diagnostics/10123-pet-scan>
- Corkin, S. (2002). What's new with the amnesic patient H.M.? *Nature Reviews Neuroscience*, 3(2), 153–160. <https://doi.org/10.1038/nrn726>
- Corkin, S., Amaral, D. G., González, R. G., Johnson, K. A., & Hyman, B. T. (1997). H. M.'s medial temporal lobe lesion: Findings from Magnetic Resonance Imaging. *The Journal of Neuroscience*, 17(10), 3964–3979. <https://doi.org/10.1523/jneurosci.17-10-03964.1997>
- Covington, N. V., & Duff, M. C. (2018, September 6). *Amnesia and the multiple memory systems of the brain*. Frontiers for Young Minds. <https://kids.frontiersin.org/articles/10.3389/frym.2018.00045>
- Cowan, N. (2013). Working memory underpins cognitive development, learning, and Education. *Educational Psychology Review*, 26(2), 197–223. <https://doi.org/10.1007/s10648-013-9246-y>
- D'Ardenne, K., Eshel, N., Luka, J., Lenartowicz, A., Nystrom, L. E., & Cohen, J. D. (2012). Role of prefrontal cortex and the midbrain dopamine system in working memory updating. *Proceedings of the National Academy of Sciences*, 109(49), 19900–19909. <https://doi.org/10.1073/pnas.1116727109>
- Davis, K. (2022, March 24). *Cognitive behavioral therapy: How does CBT work?* Medical News Today. <https://www.medicalnewstoday.com/articles/296579>
- Esther Heerema, M. S. W. (2022, February 17). *4 types of memory that everyone has*. Verywell Health. <https://www.verywellhealth.com/types-of-memory-explained-98552>
- Gibson, M., & Malik, Z. (Eds.). (2021). *Amnesia Epidemiology and demographics*. wikidoc. [https://www.wikidoc.org/index.php/Amnesia\\_epidemiology\\_and\\_demographics#:~:text=Prevalence,dissociative%20fugue%20is%20approximately%200.2%25](https://www.wikidoc.org/index.php/Amnesia_epidemiology_and_demographics#:~:text=Prevalence,dissociative%20fugue%20is%20approximately%200.2%25)
- Godman, H. (2014, April 9). *Regular exercise changes the brain to improve memory, thinking skills*. Harvard Health. <https://www.health.harvard.edu/blog/regular-exercise-changes-brain-improve-memory-thinking-skills-201404097110>
- Gropper, M. (2020). *Implicit Memory*. Implicit Memory - an overview | ScienceDirect Topics. <https://www.sciencedirect.com/topics/neuroscience/implicit-memory#:~:text=Implicit%20memory%2C%20often%20referred%20to,involved%20the%20process%20of%20priming>
- Guy-Evans, O. (2021, April 12). *Cerebellum functions, structure, and location*. Cerebellum: Functions, Structure, and Location | Simply Psychology. <https://www.simplypsychology.org/what-is-the-cerebellum.html>
- Harrison, N. A., Johnston, K., Corno, F., Casey, S. J., Friedner, K., Humphreys, K., Jaldow, E. J., Pitkanen, M., & Kopelman, M. D. (2017, August 24). *Psychogenic amnesia: Syndromes, outcome, and patterns of Retrograde amnesia*. OUP Academic. <https://academic.oup.com/brain/article/140/9/2498/4080831>

- Headway. (n.d.). *How severe is the brain injury?* Headway.  
<https://www.headway.org.uk/about-brain-injury/individuals/types-of-brain-injury/traumatic-brain-injury/how-severe-is-the-brain-injury/>
- Headway. (n.d.). *Post-traumatic amnesia.* Headway.  
<https://www.headway.org.uk/about-brain-injury/individuals/effects-of-brain-injury/post-traumatic-amnesia/>
- Heaning, E. (2022, January 13). *Henry Gustav Molaison.* Henry Gustav Molaison (Patient H.M.) - Simply Psychology. <https://www.simplypsychology.org/henry-molaison-patient-hm.html#:~:text=For%20starters%2C%20H.M%20suffered%20from,current%20research%20theorizes%20that%20H>
- Heller, L. (2015, October 5). *Korsakoff's syndrome.* Johns Hopkins Memory Disorders Center. Retrieved 2022, from [https://www.hopkinsmedicine.org/neurology\\_neurosurgery/centers\\_clinics/memory\\_disorders/conditions/korsakoffs\\_syndrome.html](https://www.hopkinsmedicine.org/neurology_neurosurgery/centers_clinics/memory_disorders/conditions/korsakoffs_syndrome.html)
- IAEA. (2016, April 13). *Radiotracers.* IAEA. <https://www.iaea.org/topics/radiotracers>
- Kumar, K. (2021, April 21). *What does it mean to have retrograde amnesia?* MedicineNet.  
[https://www.medicinenet.com/what\\_does\\_it\\_mean\\_to\\_have\\_retrograde\\_/article.htm](https://www.medicinenet.com/what_does_it_mean_to_have_retrograde_/article.htm)
- Kurlowicz, L. (1999, January). *The Mini Mental State Examination (MMSE).* The Hartford Institute For Geriatric Nursing. <https://cgatoolkit.ca/Uploads/ContentDocuments/MMSE.pdf>
- Lanciego, J. L., Luquin, N., & Obeso, J. A. (2012). Functional neuroanatomy of the basal ganglia. *Cold Spring Harbor Perspectives in Medicine*, 2(12). <https://doi.org/10.1101/cshperspect.a009621>
- Langer, K. G. (2021, June 10). *The history of amnesia-a review - current neurology and Neuroscience Reports.* SpringerLink. <https://link.springer.com/article/10.1007/s11910-021-01126-x>
- Leong, S., Waits, W., & Diebold, C. (2006). Dissociative Amnesia and DSM-IV-TR Cluster C Personality Traits. *Psychiatry (Edgmont (Pa. : Township))*, 3(1), 51–55.
- Magnetic Resonance Imaging (MRI).* Johns Hopkins Medicine. (2021, December 6).  
<https://www.hopkinsmedicine.org/health/treatment-tests-and-therapies/magnetic-resonance-imaging-mri#:~:text=What%20is%20MRI%3F,large%20magnet%20and%20radio%20waves>
- Mandal, D. A. (2019, January 22). *Diagnosis of amnesia.* News - Medical Life Sciences.  
<https://www.news-medical.net/health/Diagnosis-of-amnesia.aspx>
- Marzbani, H., Marateb, H. R., & Mansourian, M. (2016, April). *Neurofeedback: A comprehensive review on system design, methodology and clinical applications.* Basic and clinical neuroscience.  
<https://www.ncbi.nlm.nih.gov/pmc/articles/PMC4892319/>
- Mayo Foundation for Medical Education and Research. (2020, September 15). *Amnesia.* Mayo Clinic.  
<https://www.mayoclinic.org/diseases-conditions/amnesia/diagnosis-treatment/drc-20353366>

- Mayo Foundation for Medical Education and Research. (2022, August 10). *Transient global amnesia*. Mayo Clinic. <https://www.mayoclinic.org/diseases-conditions/transient-global-amnesia/symptoms-causes/syc-20378531#:~:text=Transient%20global%20amnesia%20is%20a,or%20how%20you%20got%20there>
- Mayo Foundation for Medical Education and Research. (2022, May 11). *EEG (electroencephalogram)*. Mayo Clinic. <https://www.mayoclinic.org/tests-procedures/eeg/about/pac-20393875>
- Nehring, S. M., Spurling, B. C., & Kumar, A. (n.d.). *Transient global amnesia - statpearls - NCBI bookshelf*. Retrieved <https://www.ncbi.nlm.nih.gov/books/NBK442001/>
- NYU Langone Health. (n.d.). *Diagnosing memory loss*. Patient Care at NYU Langone Health. Retrieved 2022, from <https://nyulangone.org/conditions/memory-loss-in-adults/diagnosis>
- Pinto, \*C., Hodawadekar, A., Hatle, V., & Kanekar, A. (2021, August 24). *A Review To Understand Excelsior Advances And Innovative Diagnosis Of Amnesia*. World Journal of Pharmaceutical Research [https://wjpr.net/abstract\\_file/17551](https://wjpr.net/abstract_file/17551)
- Ratini, M. (2019, May 19). *Amnesia: Types, causes, treatment, and more*. WebMD. <https://www.webmd.com/brain/what-to-know-about-amnesia>
- Smith, C. N., Frascino, J. C., Hopkins, R. O., & Squire, L. R. (2013). The nature of anterograde and retrograde memory impairment after damage to the medial temporal lobe. *Neuropsychologia*, 51(13), 2709–2714. <https://doi.org/10.1016/j.neuropsychologia.2013.09.015>
- Rosenbaum, R. S., Murphy, K. J., & Rich, J. B. (2011). The amnesias. *Wiley Interdisciplinary Reviews: Cognitive Science*, 3(1), 47–63. <https://doi.org/10.1002/wcs.155>
- Smith, C. N., Frascino, J. C., Hopkins, R. O., & Squire, L. R. (2013). The nature of anterograde and retrograde memory impairment after damage to the medial temporal lobe. *Neuropsychologia*, 51(13), 2709–2714. <https://doi.org/10.1016/j.neuropsychologia.2013.09.015>
- Squire, L. R. (2009). The legacy of patient H.M. for Neuroscience. *Neuron*, 61(1), 6–9. <https://doi.org/10.1016/j.neuron.2008.12.023>
- Vitelli, R. (2014, April 14). *Exploring childhood amnesia*. Psychology Today. <https://www.psychologytoday.com/us/blog/media-spotlight/201404/exploring-childhood-amnesia>
- Where are memories stored in the brain?* Queensland Brain Institute - University of Queensland. (2018, July 23). <https://qbi.uq.edu.au/brain-basics/memory/where-are-memories-stored>